ECOGRAFIA TORACICA e COVID

AdET ACCADEMIA di ECOGRAFIA TORACICA

30 settembre 2020

ECOGRAFIA TORACICA E COVID19 IN TERAPIA INTENSIVA

Gianluca Russo MD PhD, Anaesthesiologist ASST LODI

RESPONSABILI SCIENTIFICI:
G. Soldati, F. Tursi

WEBINAR

COVID-19 CRITICAL PATIENTES

- **China → 1 – 6%** (WHO-China Joint Mission on Coronavirus Disease 2019 (COVID-19). Feb 28, 2020.
- **Italy → Up to 12%** (Grasselli G et al Critical care utilization for the COVID-19 outbreak in Lombardy, Italy: early experience and forecast during an emergency response. *JAMA* 2020; published online March 13)

ICU admissions are dependent on the severety of illness and the ICU capacity of the Health-care system

COVID-19 CRITICAL PATIENTES

- Older and more comorbidities
- Common symptoms not specific: fever, cough, fatigue and dyspnoea
- Median time from symptom onset to severe hypoxaemia and ICU admission is 7 – 12 days (Yang X et al. *Lancet Respir Med* 2020; Arentz M et al. *JAMA* 2020).

ARDS (acute respiratory distress syndrome) → 60-70 %

Shock → 30%

Myocardial dysfuction → 20-30%

Acute kidney injury → 10-30%

Intensive care management of coronavirus disease 2019 (COVID-19): challenges and recommendations

Jason Phua, Li Weng, Lowell Ling, Moritoki Egi, Chae-Man Lim, Jigeeshu Vasishtha Divatia, Babu Raja Shrestha, Yaseen M Arabi, Jensen Ng, Charles D Gomersall, Masaji Nishimura, Younsuck Koh, Bin Du, for the Asian Critical Care Clinical Trials Group

Lancet Respir Med 2020; 8: 506–17

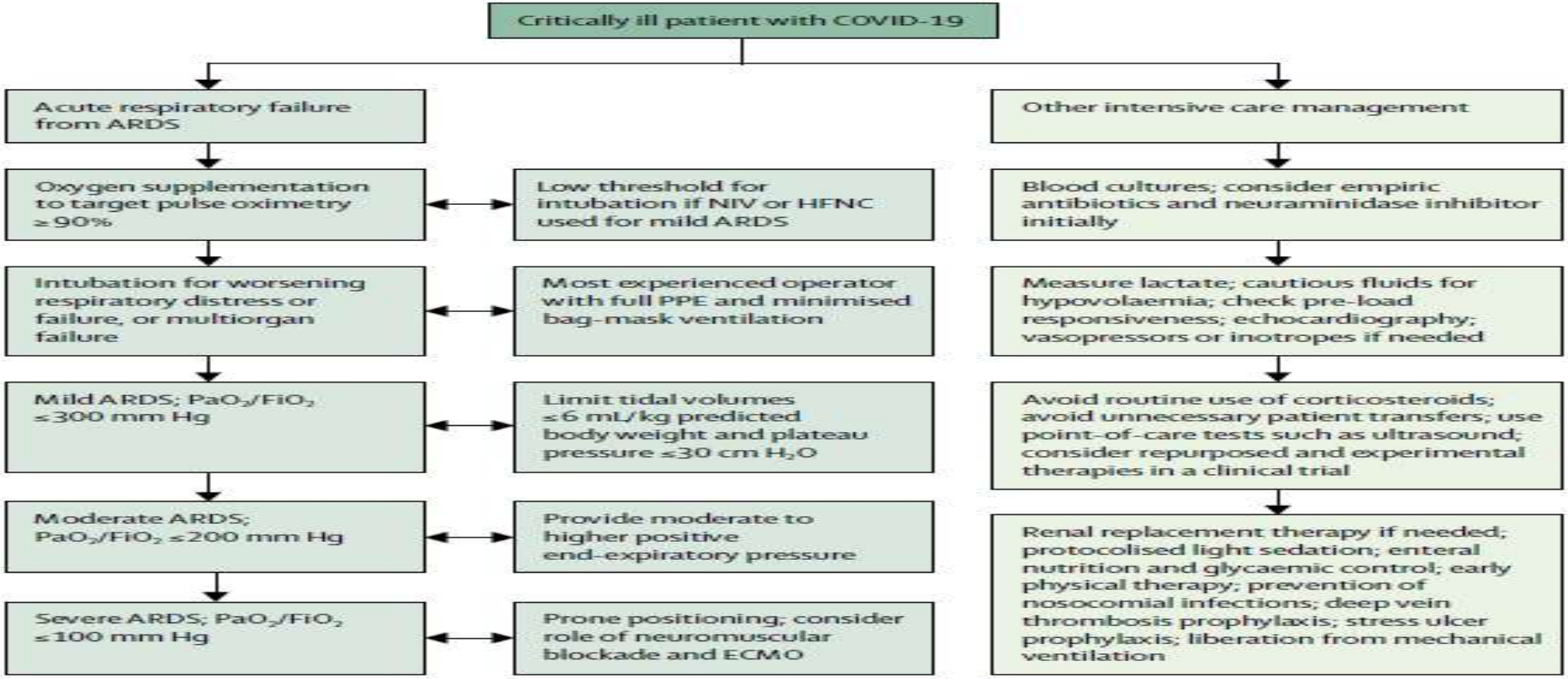

Why POCUS should be a priority in Covid?

High sensitivity but low specificity.

Fast at bedside and reproducible for monitoring disease course

Cheaper test



Easier to disinfect equipment compared to CT scan

Easy in trained staff

Avoid patientes transfer and ionising radiations

Box 1. List of Medline articles on POCUS in the COVID-19 pandemic, in chronological order

Peng *et al.*[9]

A letter to the editor describing their initial experience with POCUS in China. They were the first group to describe the ultrasound imaging features of COVID-19 and suggest it as an alternative to other imaging methods

Buonsenso *et al.*[10]

A case report of a young man with COVID-19 in Italy, describing acquisition technique and imaging findings

Soldati *et al.*[11]

A letter asking the question "Is there a role for lung ultrasound during the COVID-19 pandemic?" The article covers the imaging features, acquisition technique, and practical advantages of using POCUS

Moro *et al.*[12]

In this article, the authors wrote a tutorial on how to perform lung ultrasound in pregnant women with suspected COVID-19, primarily targeted at an audience of gynaecologists

Soldati *et al.*[13]

Based on their clinical experience in Italy, Soldati *et al.* set out to propose an international standardised approach to POCUS in COVID-19. The authors describe a reproducible acquisition protocol and scoring system

Thomas *et al.*[14]

The first POCUS paper from North America during the COVID-19 pandemic. Thomas *et al.* describe the case of a 64-year-old woman with COVID-19, confirming the imaging findings of previous authors

Vetrugno *et al.*[15]

The authors reported their experience using lung ultrasound scoring in Italy

Kalafat *et al.*[16]

The authors report the case of a pregnant woman in Turkey admitted to ICU due to COVID-19. POCUS contributed to early clinical decisions in the ICU

Proposal for International Standardization of the Use of Lung Ultrasound for Patients With COVID-19

A Simple, Quantitative, Reproducible Method

Gino Soldati, MD, Andrea Smargiassi, MD, PhD, Riccardo Inchingolo, MD, Danilo Buonsenso, MD, Tiziano Perrone, MD, PhD, Domenica Federica Briganti, MD, Stefano Perlini, MD, PhD, Elena Torri, MD, Alberto Mariani, MD, Elisa Eleonora Mossolani, MD, Francesco Tursi, MD, Federico Mento, MSc, Libertario Demi, PhD

LUS could be useful, being performed at several time points from clinical diagnosis, in determining early lung involvement during the paucisymptomatic phase of the disease and potentially playing a role in treatment decisions.

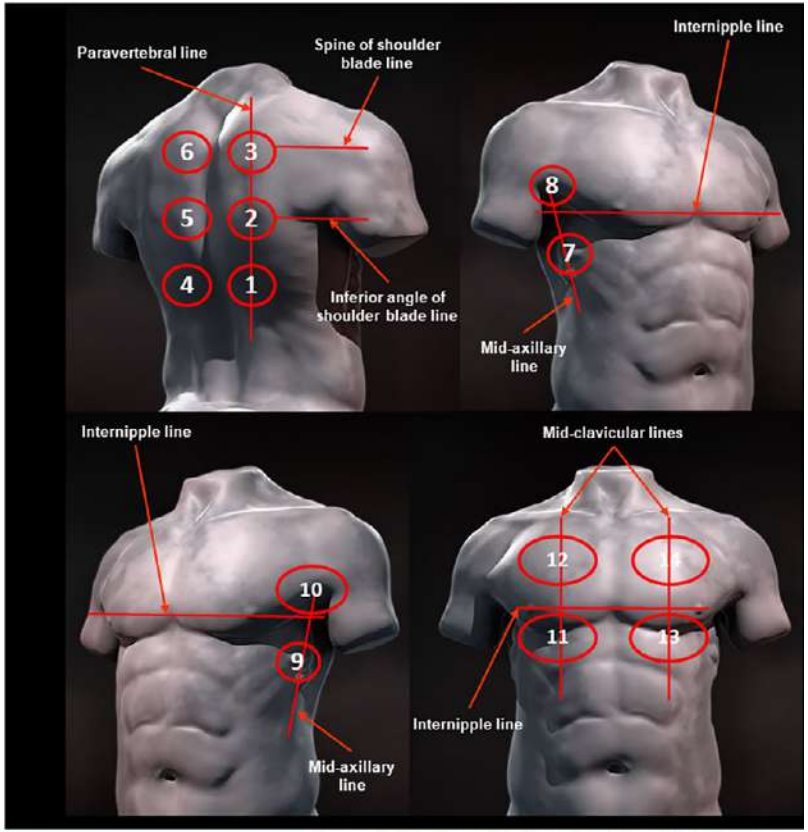

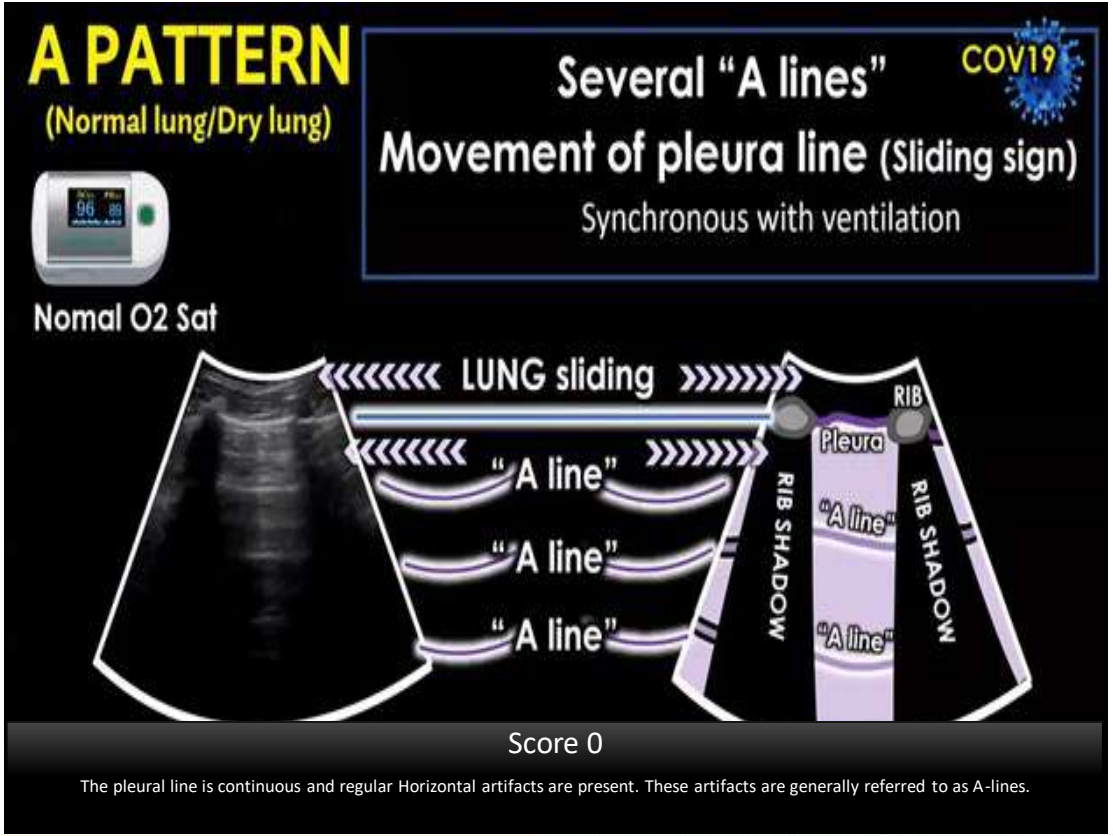
A PATTERN
(Normal lung/Dry lung)
Several "A lines"
COV19
Movement of pleura line (Sliding sign)
Synchronous with ventilation
Nomal O2 Sat
LUNG sliding
"A line"
"A line"
"A line"
RIB
Pleura
RIB SHADOW
"A line"
"A line"
RIB SHADOW
Score 0
The pleural line is continuous and regular Horizontal artifacts are present. These artifacts are generally referred to as A-lines.

B PATTERN

(Mild pulmonary disease/wet lung)

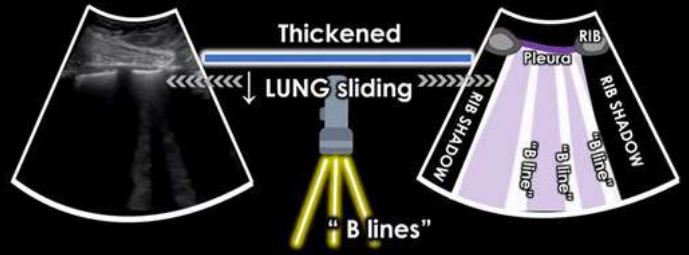

Score 1

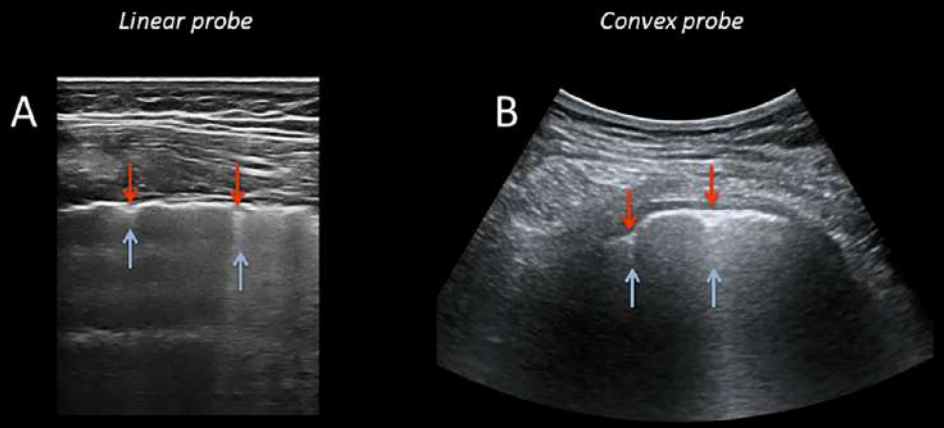

SCORE 1

The pleural line is indented. Below the indent, vertical areas of white are visible

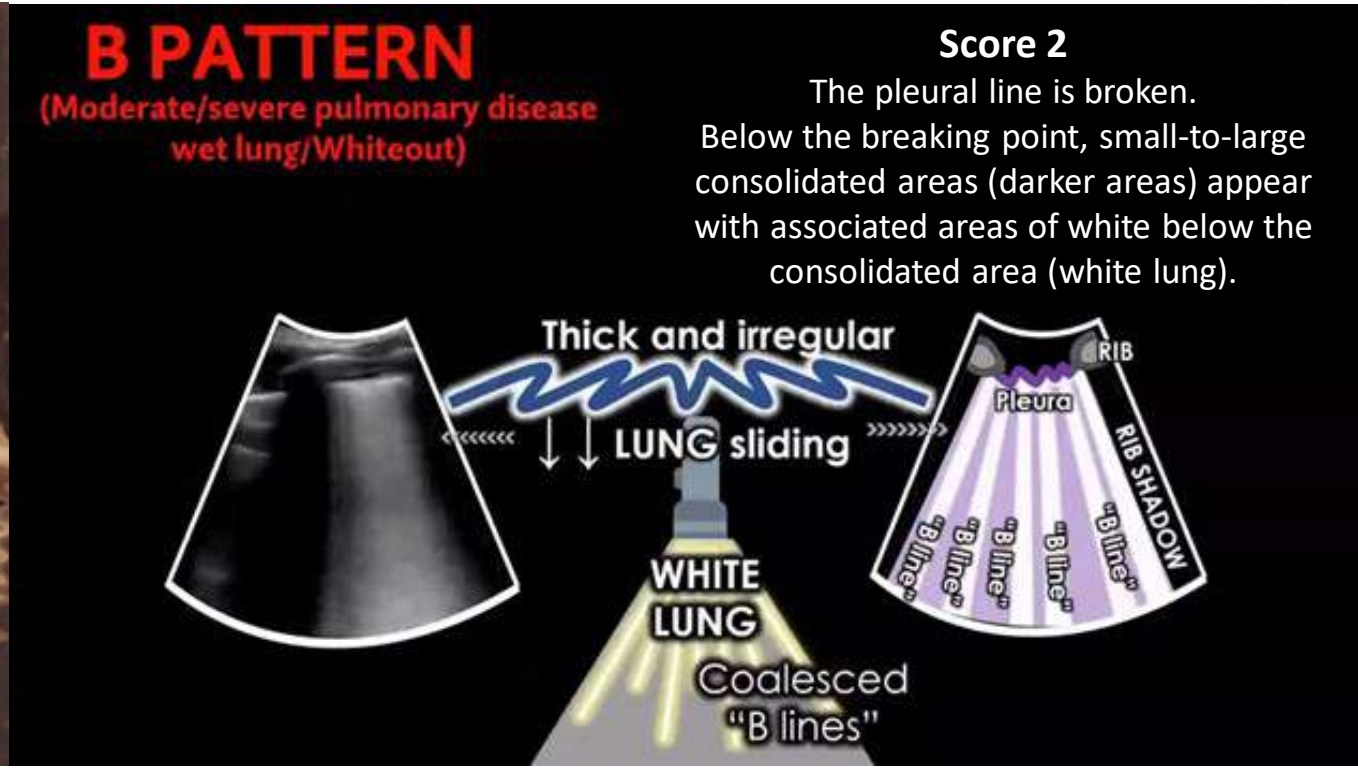

Score 2

The pleural line is broken.
Below the breaking point, small-to-large consolidated areas (darker areas) appear with associated areas of white below the consolidated area (white lung).

CONSOLIDATION

(Severe pulmonary disease)

COV19

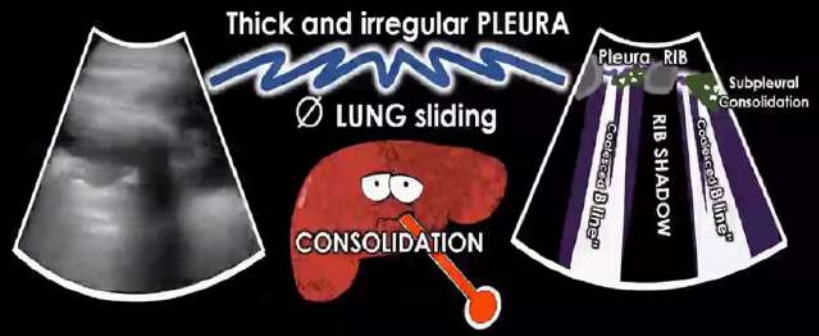

Score 3

The scanned area shows dense and largely extended white lung with or without larger consolidations.

Score 3

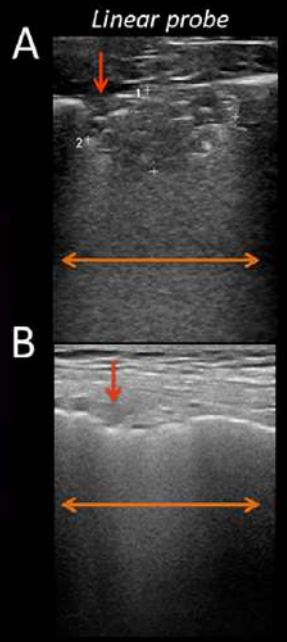

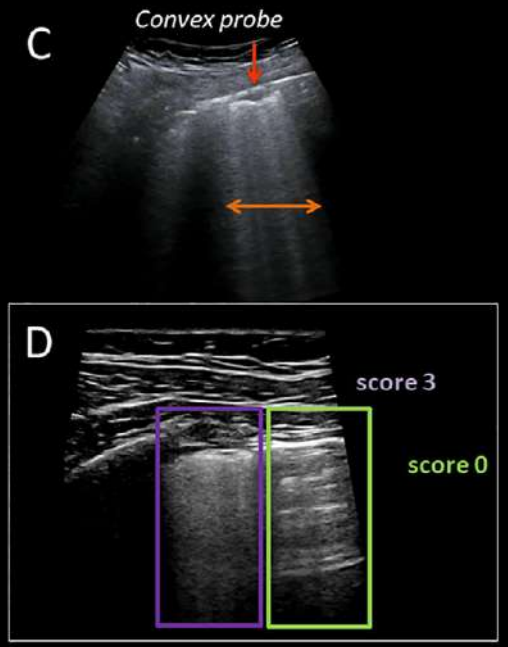

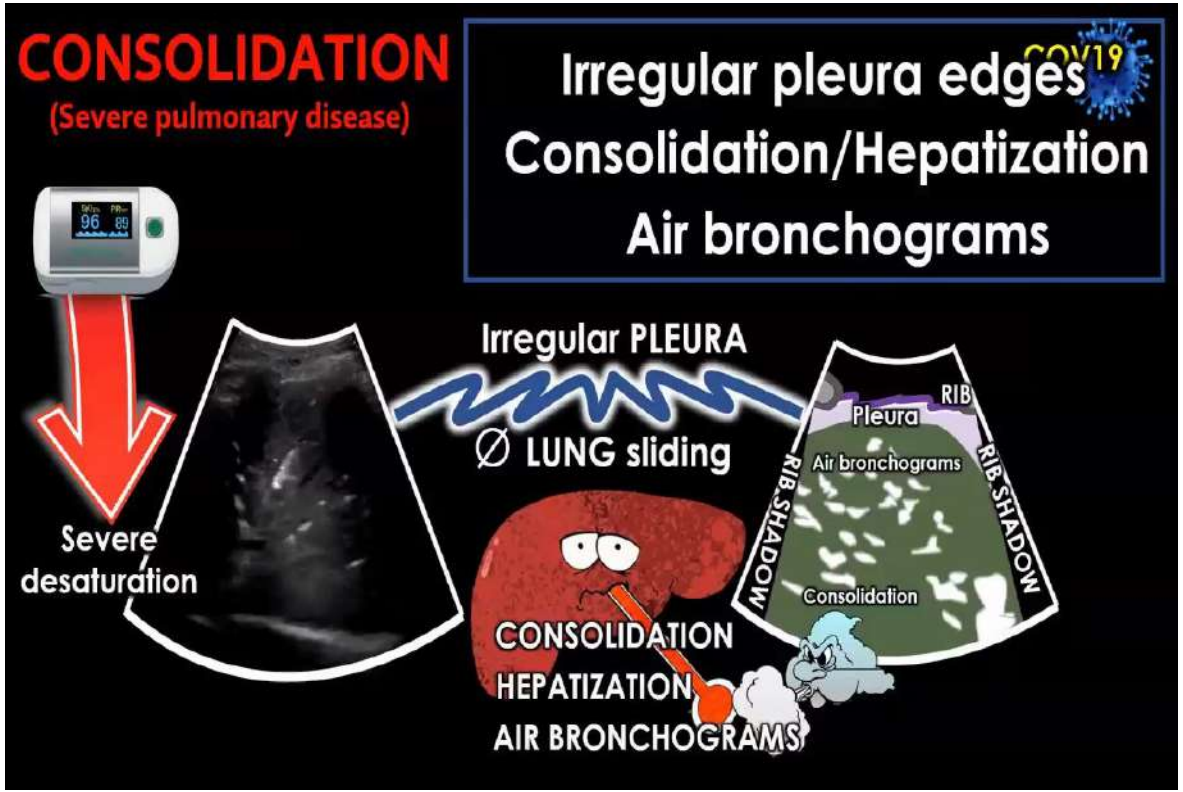
CONSOLIDATION
(Severe pulmonary disease)
Irregular pleura edges
Consolidation/Hepatization
Air bronchograms
COV19
Severe desaturation
Irregular PLEURA
Ø LUNG sliding
RIB
Pleura
Air bronchograms
RIB SHADOW
RIB SHADOW
Consolidation
CONSOLIDATION
HEPATIZATION
AIR BRONCHOGRAMS

REVIEW ARTICLE

Echocardiography WILEY

Our Italian experience using lung ultrasound for identification, grading and serial follow-up of severity of lung involvement for management of patients with COVID-19

Luigi Vetrugno MD[1,2] | Tiziana Bove MD[1,2] | Daniele Orso MD[1] |
Federico Barbariol MD[2] | Flavio Bassi MD[2] | Enrico Boero MD[3] |
Giovanni Ferrari MD[4] | Robert Kong MD, FRCA, EDIC[5]

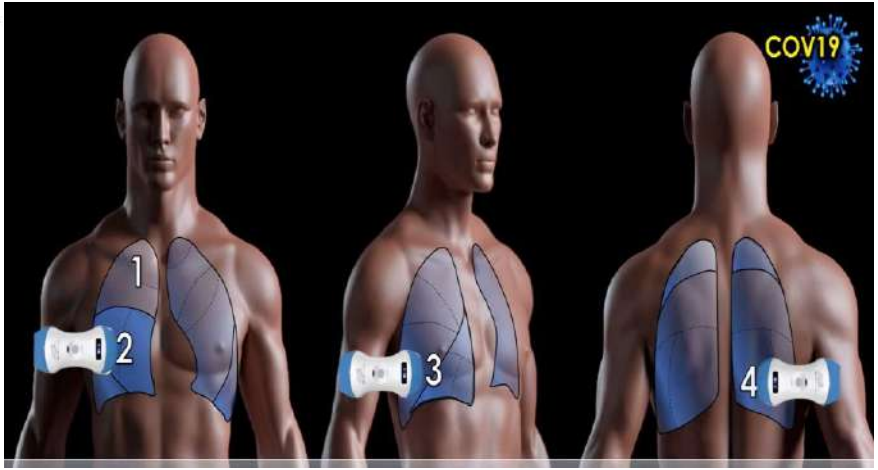

A scan of the three different areas of the thorax:
anterior, lateral, and **posterior**, and then **superior** and **inferior** segments are performed.
Thus, *six specific regions for each lung* are defined and categorized by one of four different aeration patterns.
A point scoring system is employed by region and ultrasound pattern as:

A = 0 point, B1 = 1 point, B2 = 2 points, C = 3 points.

LUS of 0 is normal, and 36 would be the worst.

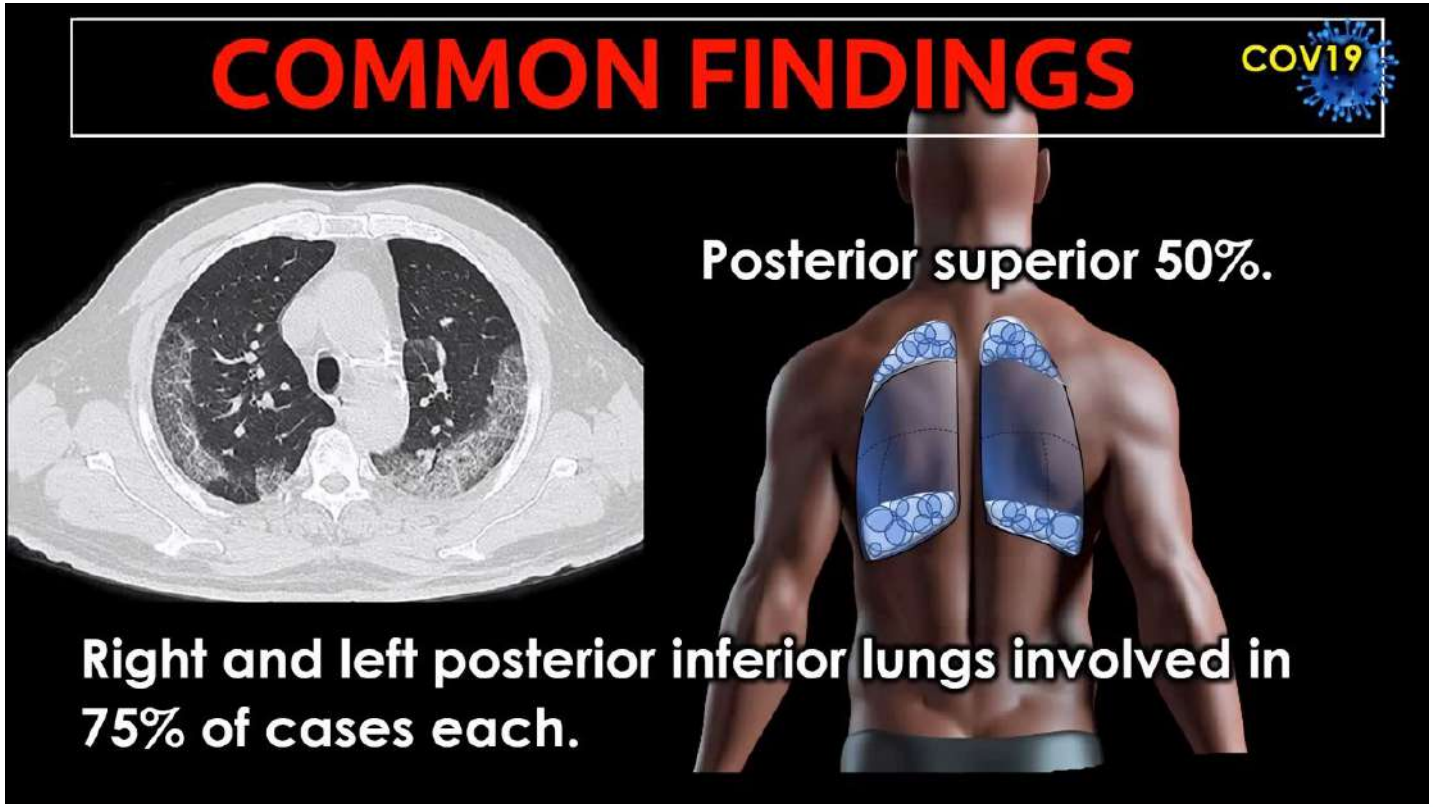
COMMON FINDINGS
COV19
Posterior superior 50%.
Right and left posterior inferior lungs involved in 75% of cases each.

Anaesthesia 2020 doi:10.1111/anae.15082

Review Article

Point-of-care lung ultrasound in patients with COVID-19 – a narrative review

M. J. Smith,[1] S. A. Hayward,[2] S. M. Innes[3] and A. S. C. Miller[4]

By informing the initiation, escalation, titration andweaning of respiratory support, lung ultrasound can be integrated into COVID-19 care pathways for patients with respiratory failure.

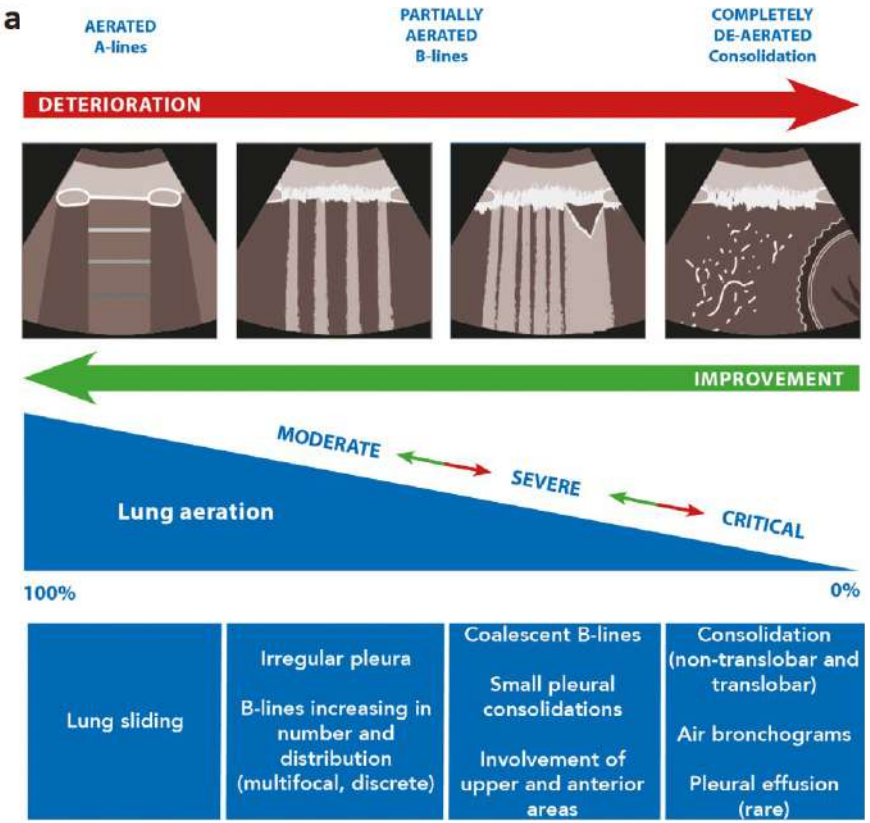

Point-of-care lung ultrasound in patients with COVID-19 – a narrative review

Table 2 A simplified description of where in the COVID-19 patient care pathway lung ultrasound is of most use.

Severity of COVID-19–related lung injury	Typical sonographic characteristics	Typical clinical characteristics
Pre-disease to moderate	Development of B-lines which begin to increase in number and distribution. The pleural line begins to become irregular. Areas with B-lines are adjacent to normal areas of lung sliding and A-lines. These are 'skip lesions' or 'spared areas'. Small (~1 cm) consolidations.	Respiratory rate > 30 min^{-1}. Oxygen saturations ≤93% on room air. The need for supplemental oxygen. Lung tissue begins to lose aeration.
Severe	B-lines continue to increase in number and distribution, and begin to affect the upper and anterior areas of the lungs. B-lines become coalescent/confluent. Small consolidations increase in number and size.	Oxygen saturations ≤ 93% on supplementary oxygen. Clinical signs of respiratory distress. The need for additional supplemental oxygen or respiratory support. Lung tissue is becoming progressively de-aerated.
Critical	Extensive coalescent B-lines affect the upper and anterior areas of the lungs. Significant small consolidations affect the upper and anterior areas of the lungs. Posterio-basal sections of the lungs have significant bilateral alveolar interstitial syndrome progressing to consolidation with or without air bronchograms. Pleural effusions are small or rare unless the patient's fluid balance is high.	Likely to be or require invasive mechanical ventilation. The need for a high fraction of inspired oxygen. Dependent areas of lung tissue have becoming non-aerated.

COVID-19 pneumonia: different respiratory treatments for different phenotypes?

Luciano Gattinoni[1*], Davide Chiumello[2], Pietro Caironi[3,4], Mattia Busana[1], Federica Romitti[1], Luca Brazzi[5] and Luigi Camporota[6]

A

PaO_2/FiO_2
95 mmHg

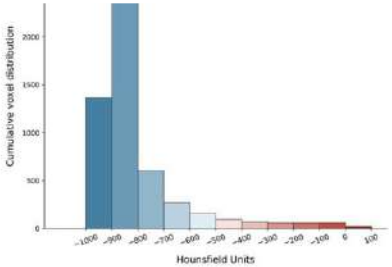

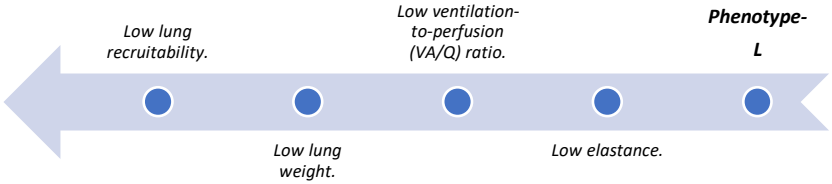

B

PaO_2/FiO_2
84 mmHg

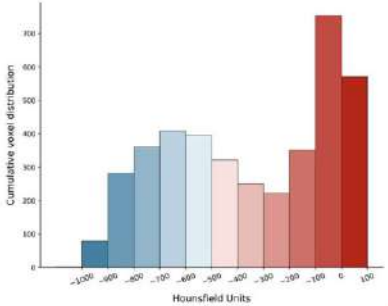

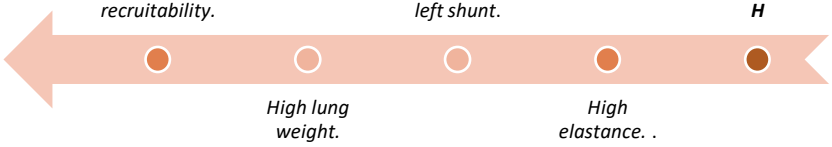

Respiratory Treatment

The first step to reverse hypoxemia is through an increase in FiO2 to which the Type L patient responds well, particularly if not yet breathless.

In Type L patients with dyspnea, several noninvasive options are available but continuous positive airway pressure (CPAP) should be preferred..

The magnitude of inspiratory pleural pressures swings may determine the transition from the Type L to the Type H phenotype. As esophageal pressure swings increase from 5 to 10 cmH2O—which are generally well tolerated—to above 15 cmH2O, the risk of lung injury increases and therefore intubation should be performed as soon as possible.

Respiratory Treatment

Once intubated and deeply sedated, the Type L patients, if hypercapnic, can be ventilated with volumes greater than 6 ml/kg (up to 8–9 ml/kg), as the high compliance results in tolerable strain without the risk of VILI.

Prone positioning should be used only as a rescue maneuver, as the lung conditions are “too good” for the prone position effectiveness, which is based on improved stress and strain redistribution.

The PEEP should be reduced to 8–10 cmH2O, given that the recruitability is low and the risk of hemodynamic failure increases at higher levels.

An early intubation may avert the transition to Type H phenotype.

Type H patients should be treated as severe ARDS, including higher PEEP, if compatible with hemodynamics, prone positioning and extracorporeal support.

Conclusions

POCUS has a high sensitivity for the pulmonary manifestations of COVID-19, such as ARDS and consolidation.

Furthermore, POCUS can be used to monitor treatment response. POCUS is an asset to hospitals as it minimizes nosocomial spread of the disease.

Application of LUS has allowed for identification of patients with lung involvement and severity. In addition, serial studies help us follow for progression or regression of disease.

With the application of LU we have had a noted reduction in use of chest x-rays and CT scans, helping us to make care and management of our patients a little more efficient.

Am J Respir Crit Care Med. 2018 Oct 29. doi: 10.1164/rccm.201802-0236(

Lung Ultrasound for Critically Ill Patients.

Mojoli F[1], Bouhemad B[2], Mongodi S[3], Lichtenstein D[4].

Conclusions

Lung ultrasound is a simple bedside technique with numerous potential translational applications. It may help physicians in the diagnosis of the main respiratory disorders affecting the critically ill, thus suggesting the therapeutic approach in the emergency department and ICU.

Lung ultrasound can be employed to assess and monitor lung aeration in the acute respiratory failure patient and may be a useful tool to guide mechanical ventilation and several procedures, such as recruitment maneuvers, pronation, fiber-bronchoscopy and pleural drainage.

As a consequence, lung ultrasound has generated worldwide enthusiasm among physicians involved in the treatment of critically ill patients. Many clinical applications are nowadays suggested: the extent of their clinical impact and whether lung ultrasound should be part of the basic knowledge of all intensivists will be assessed in the next future.A


Thanks